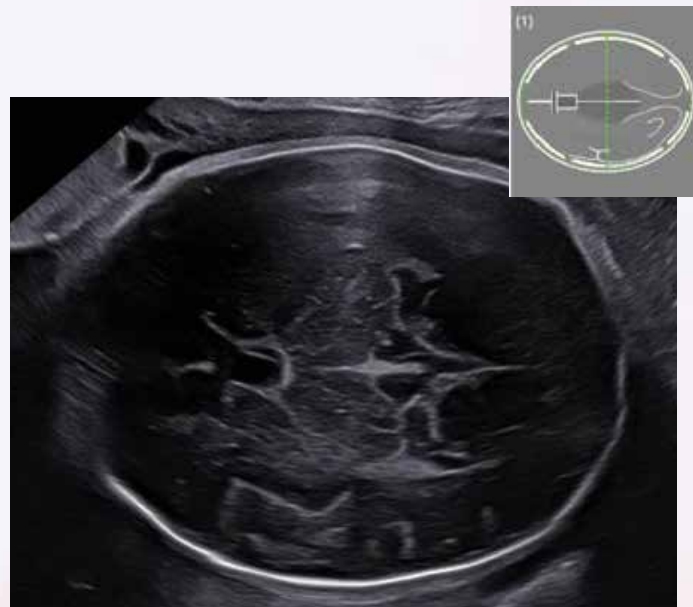
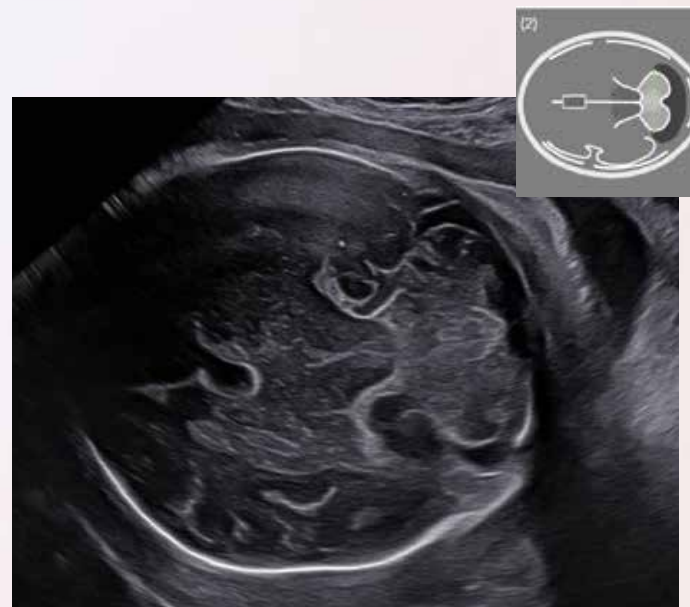

Iconographie recommandée par la CNEOF

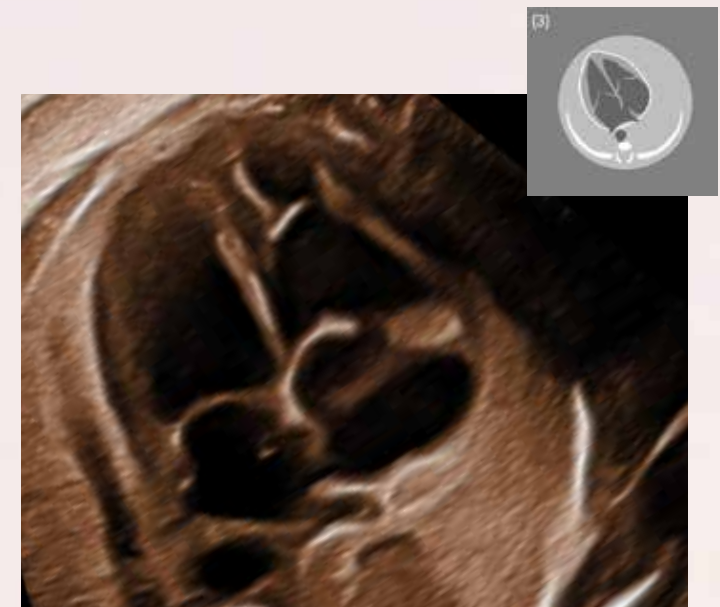
Trimestre 3



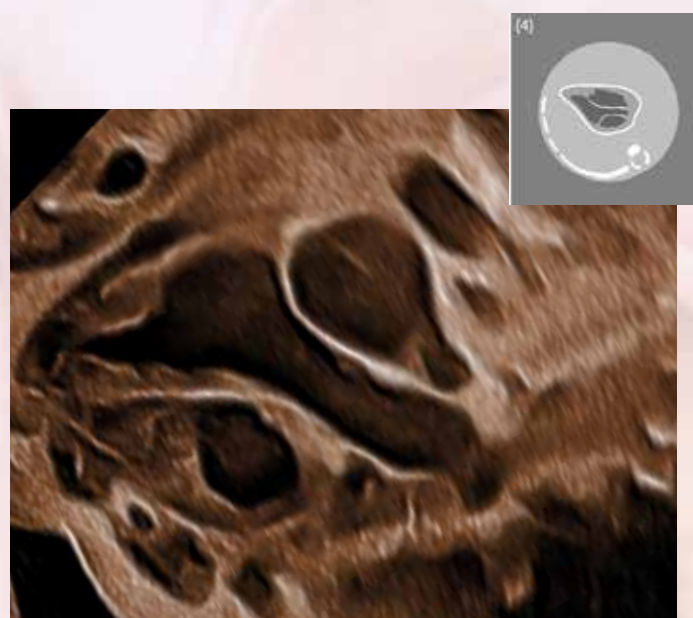
Cervelet



BIP PC



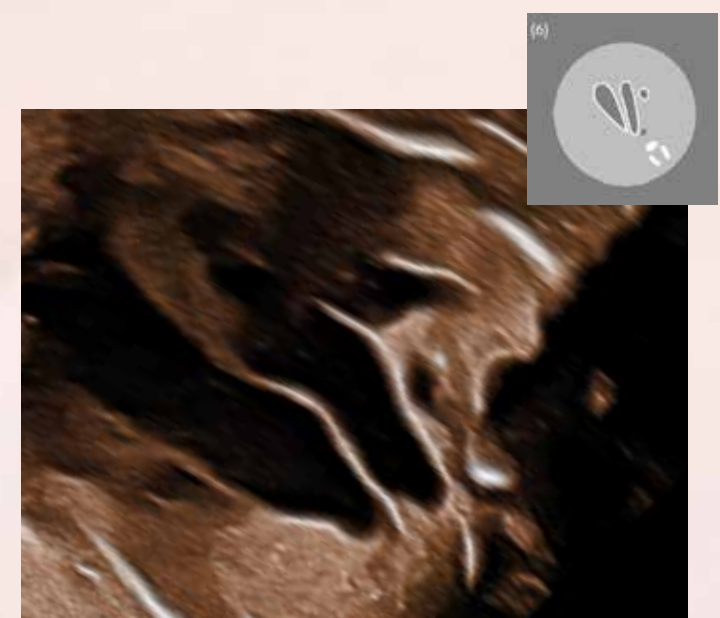4 cavités cardiaques



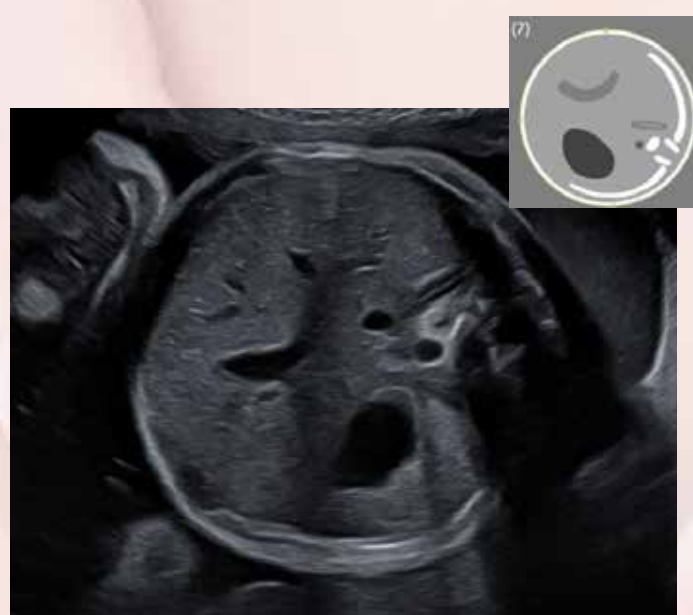VG aorte



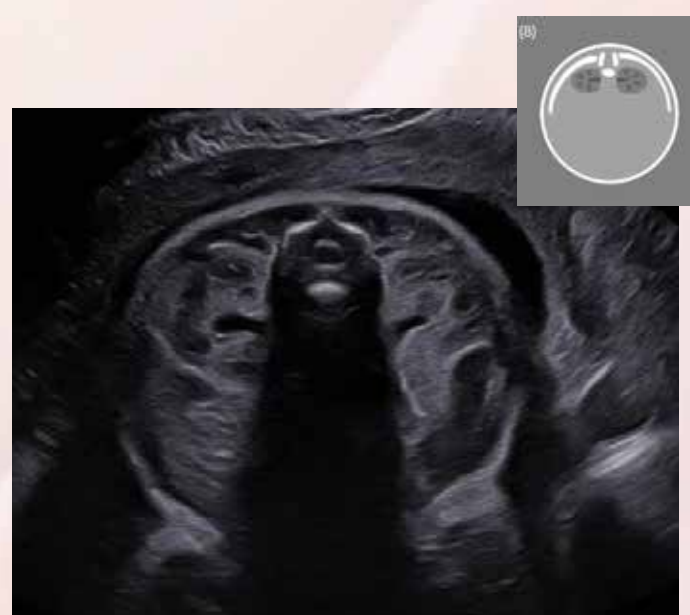Bifurcation AP



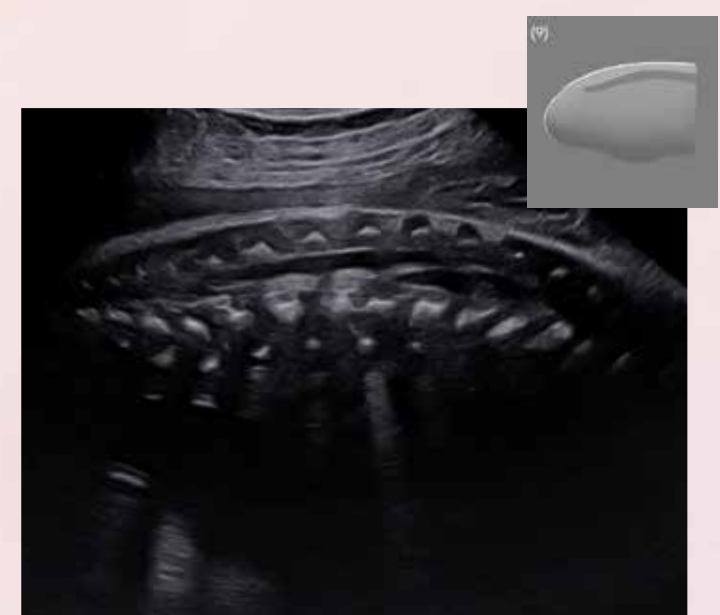
Coupe des crosses



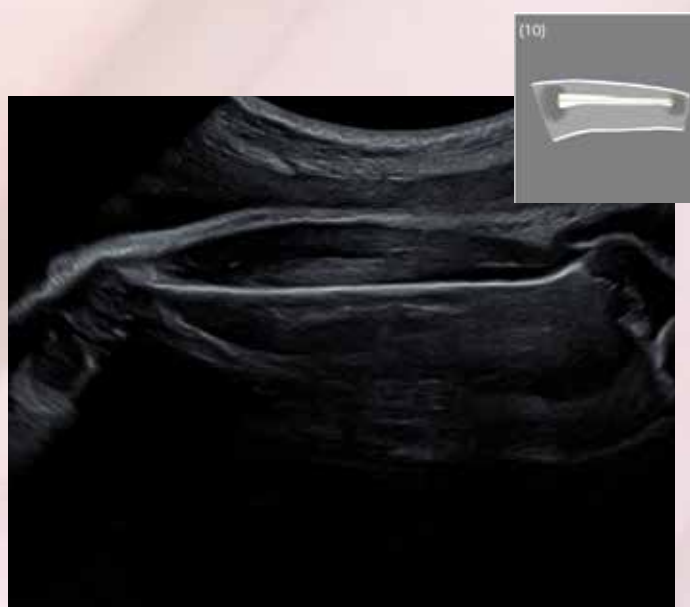Abdomen



Reins



Rachis



Fémur