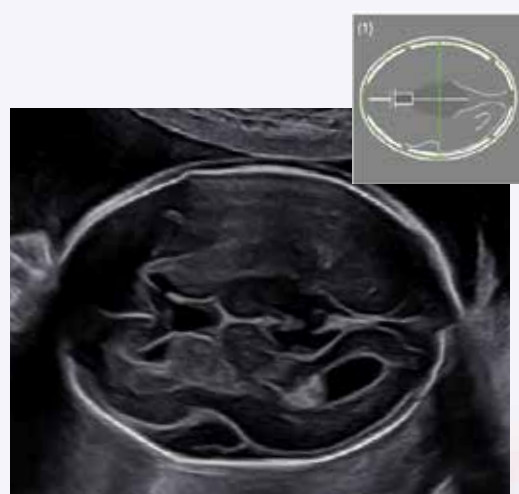
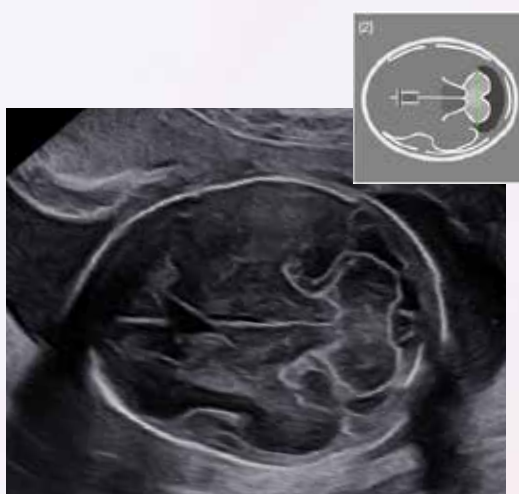

## Iconographie recommandée par la CNEOF

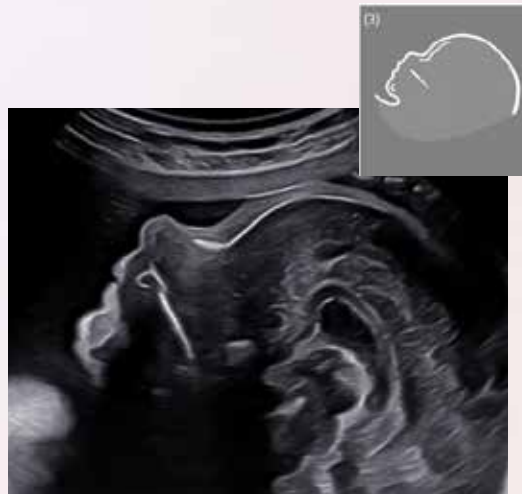
Trimestre 2



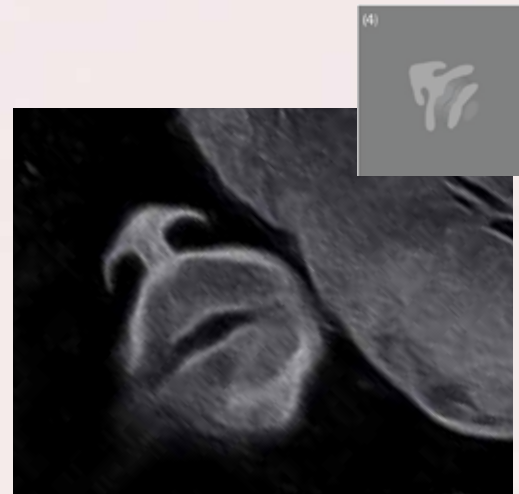BIP PC



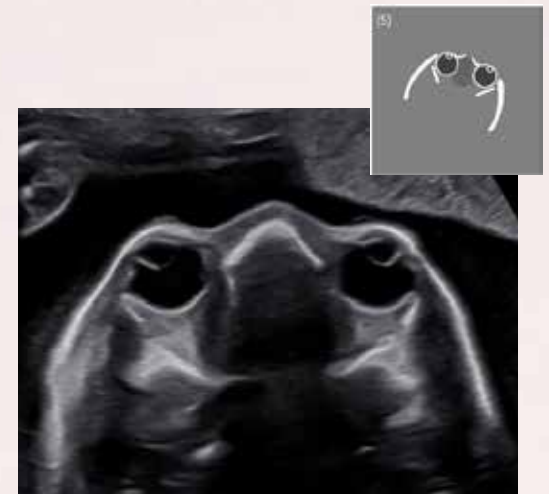
Cervelet



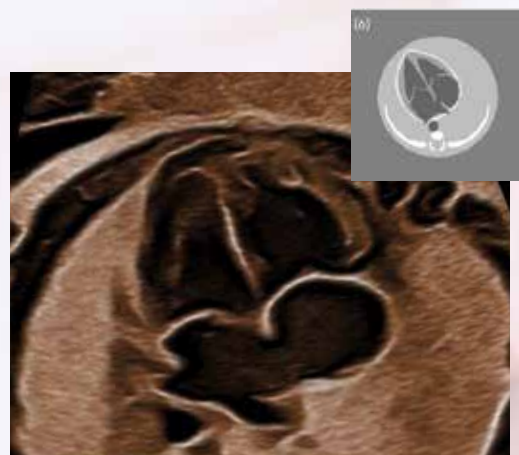
Profil



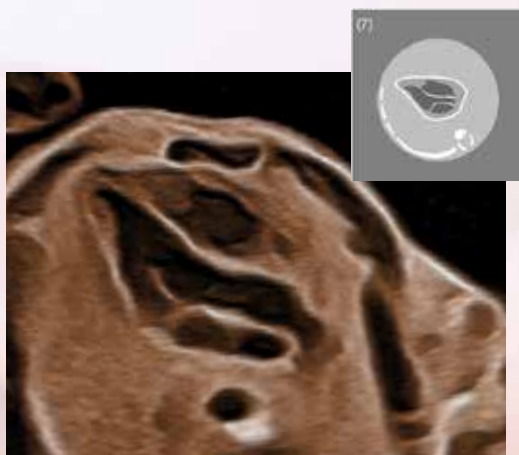
Nez-lèvres



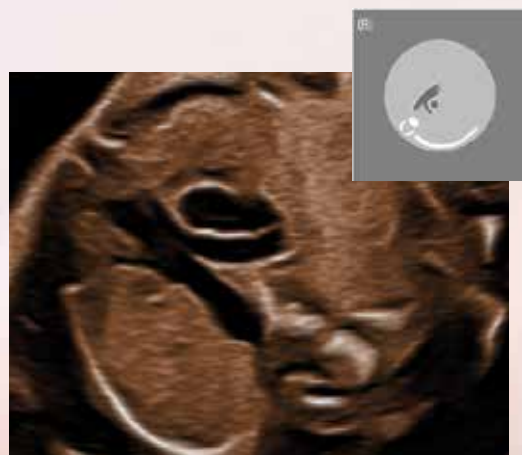Orbites



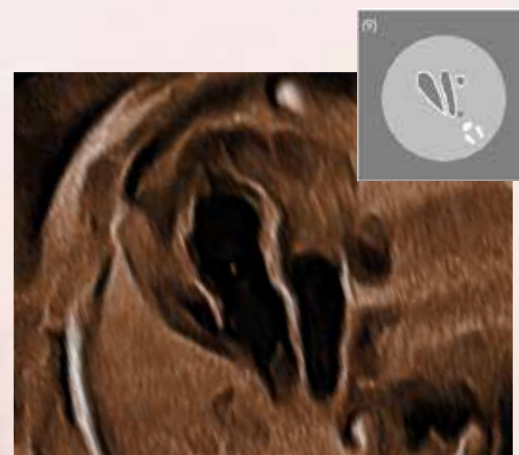
4 cavités



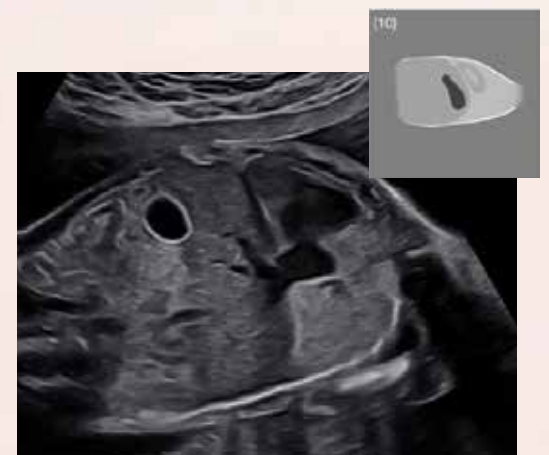
VG Aorte



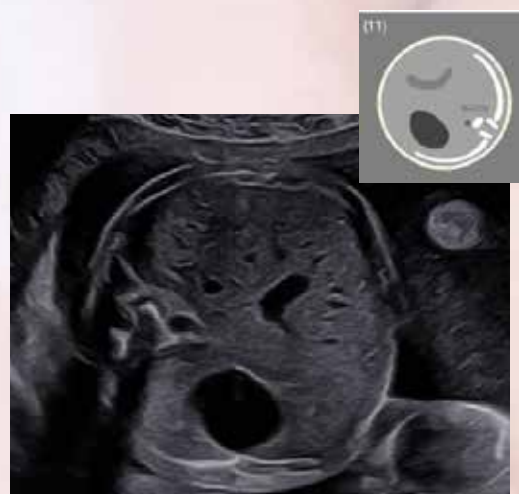Bifurcation AP



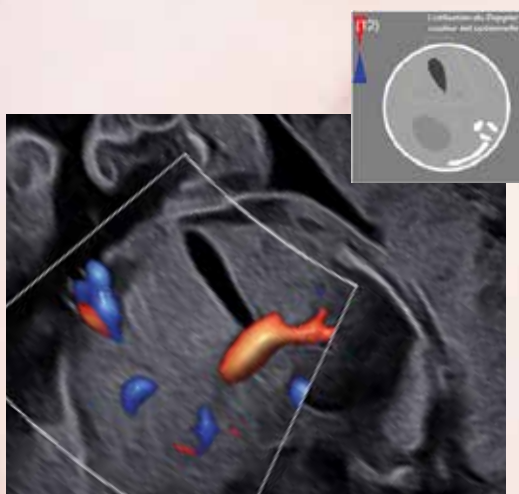
Coupe des crosses



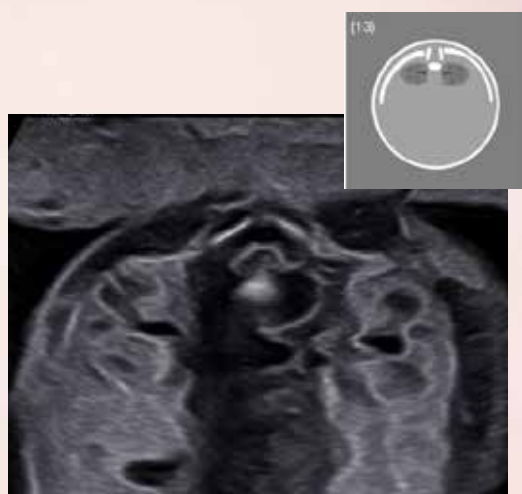
Diaphragme



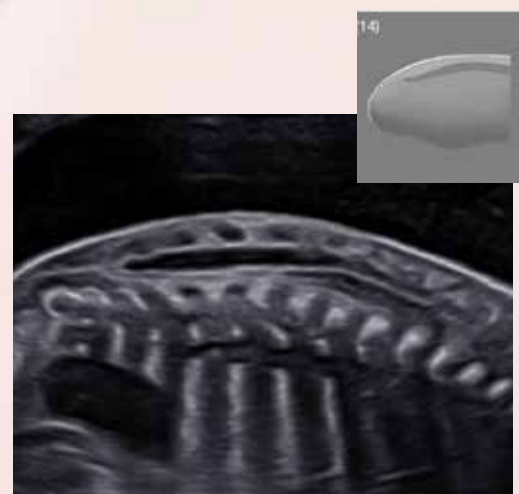
Abdomen



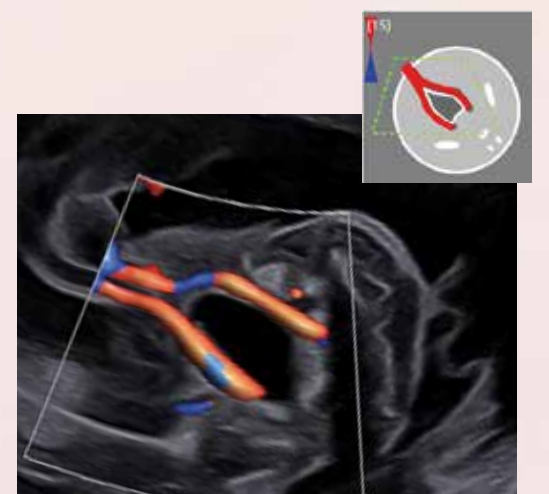
Vesicule Biliaire



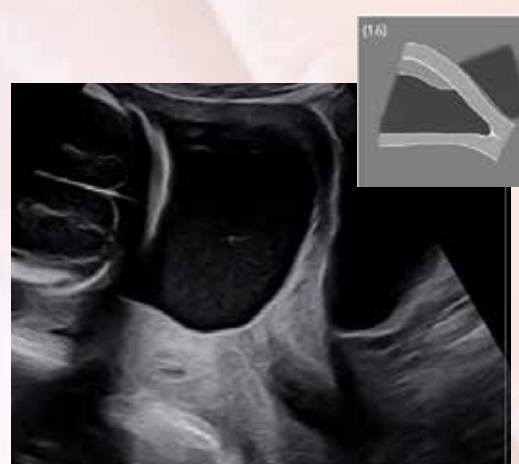
Reins



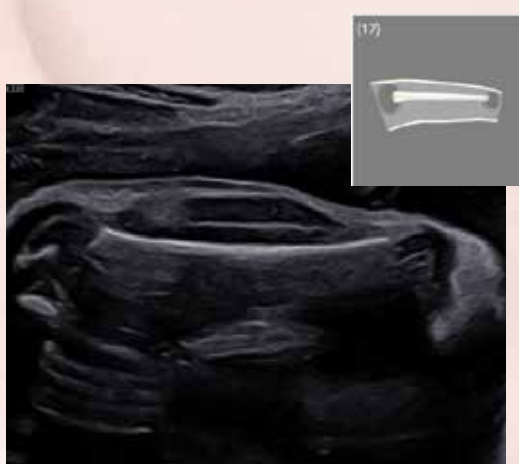Rachis



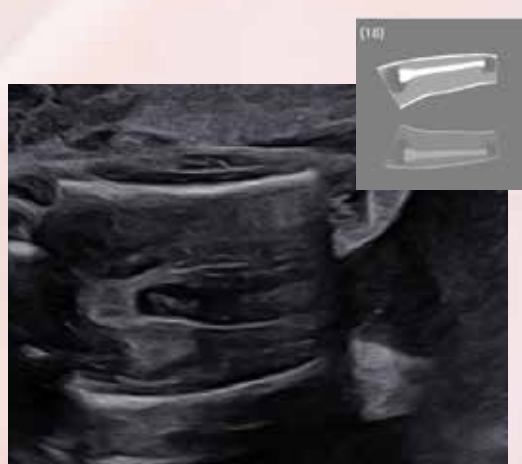
Vessie



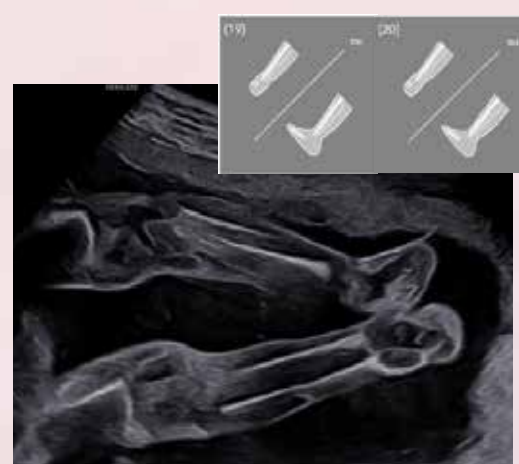
Placenta - OI



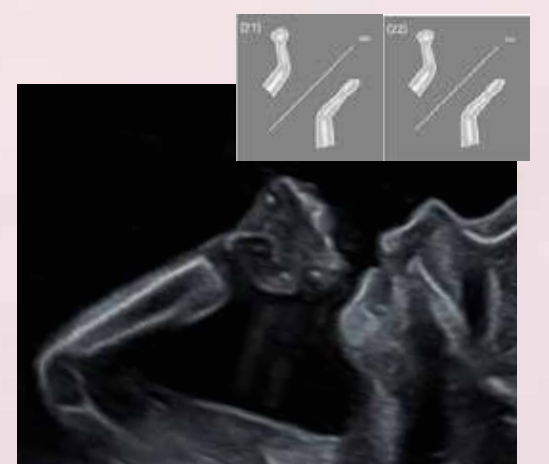
Fémur



Deux fémurs

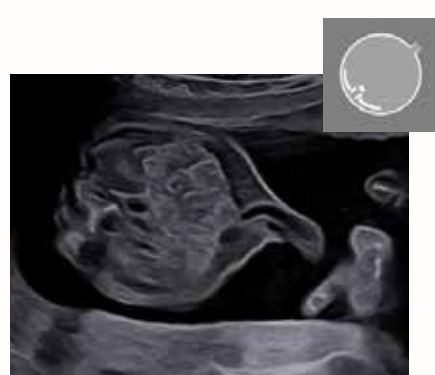


Membres inférieurs

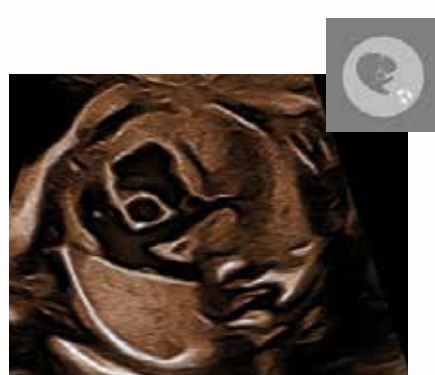

Membres supérieurs

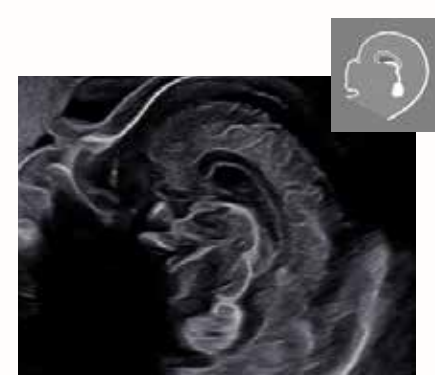
### Images Complémentaires



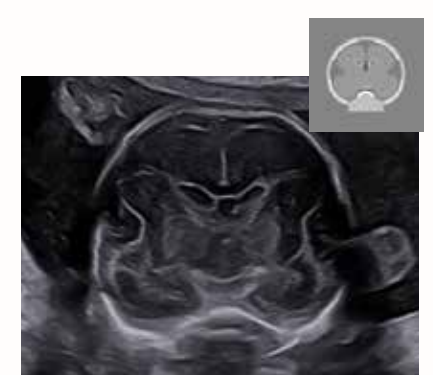Insertion du cordon



Voie d'éjection droite



Pôle céphalique Coupe sagittale



Pôle céphalique Coupe coronale