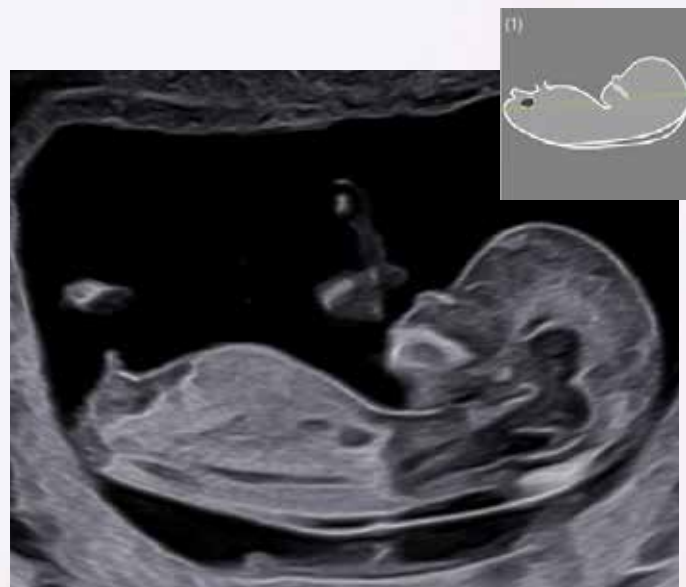
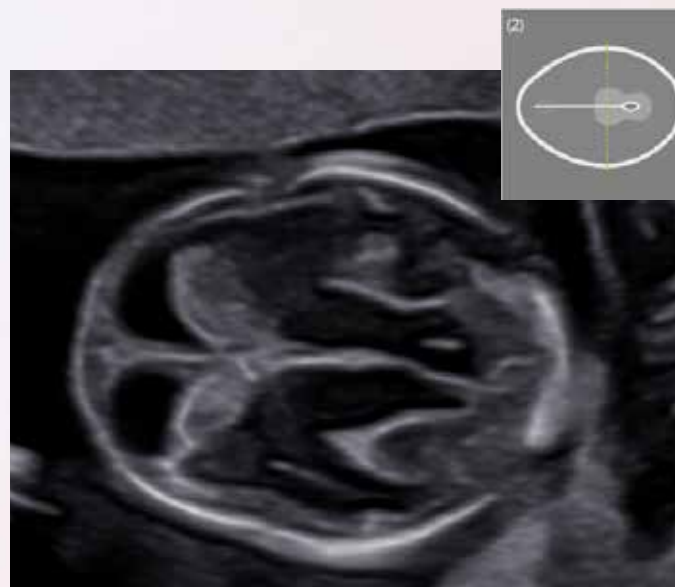

## Iconographie recommandée par la CNEOF

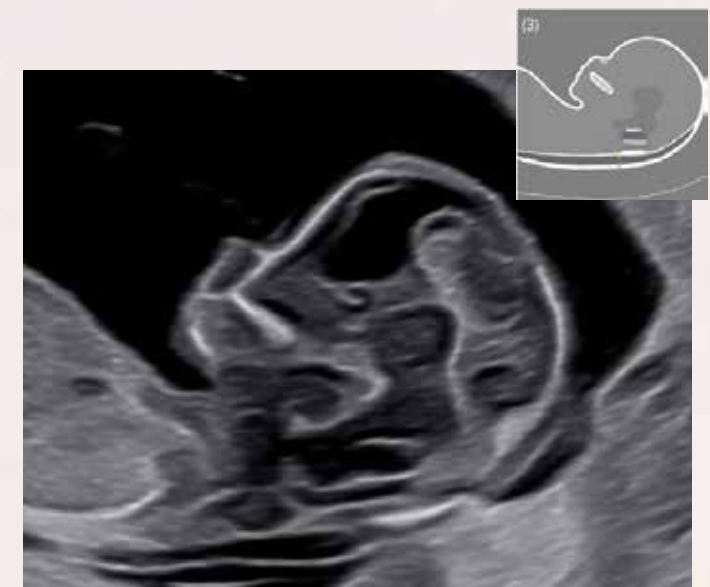Trimestre 1



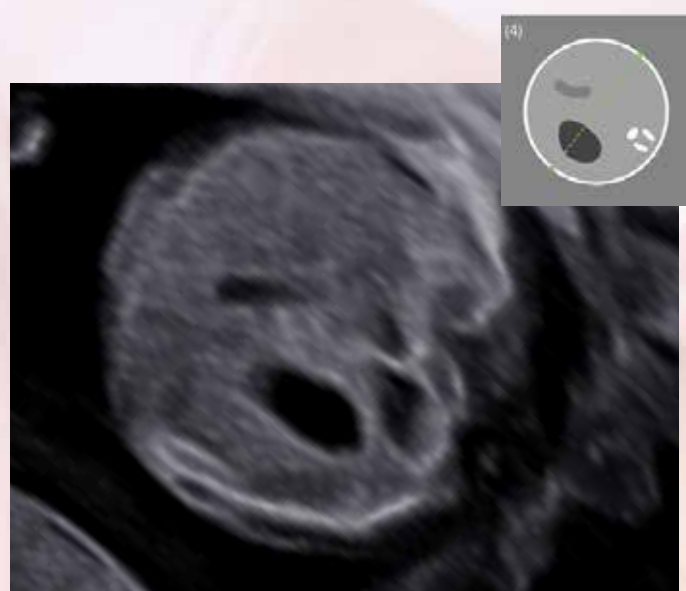
LCC



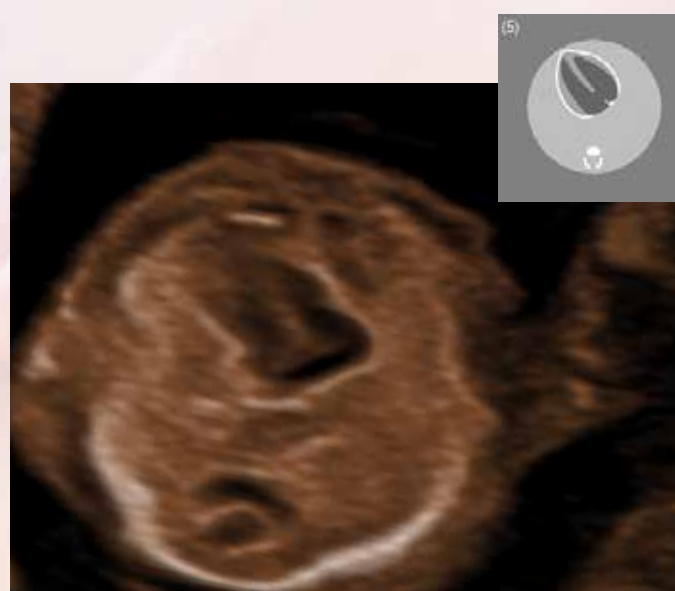BIP PC



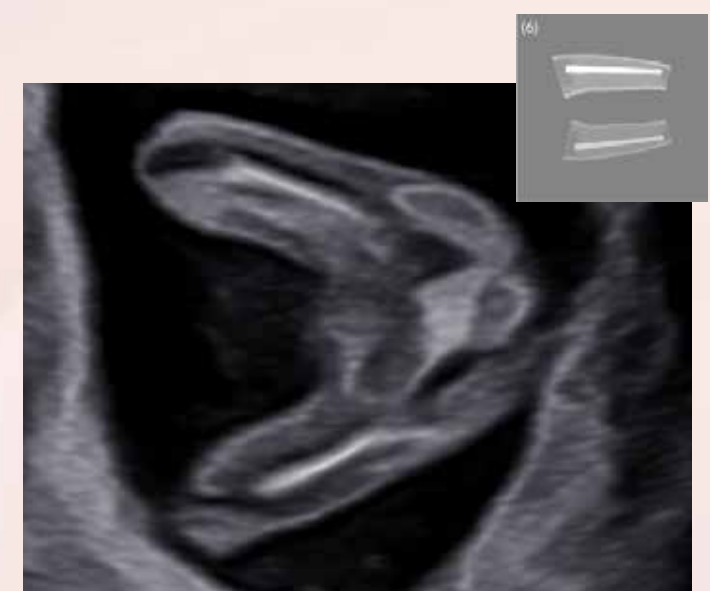Clarté nucale



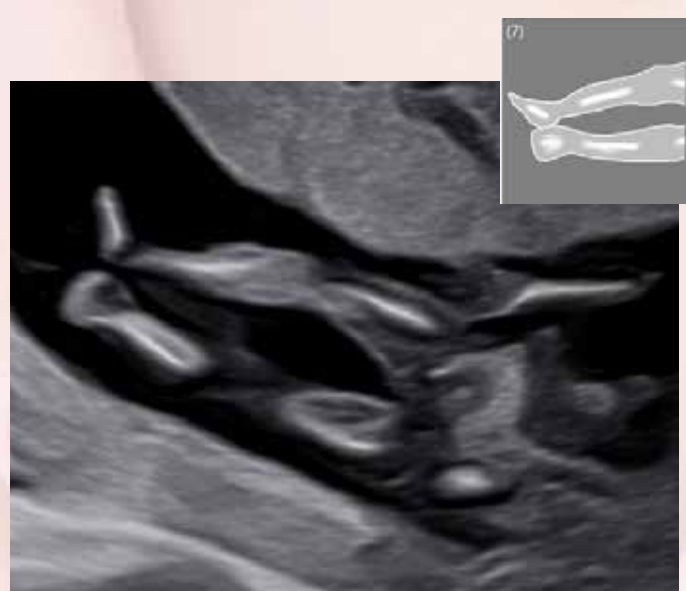Abdomen



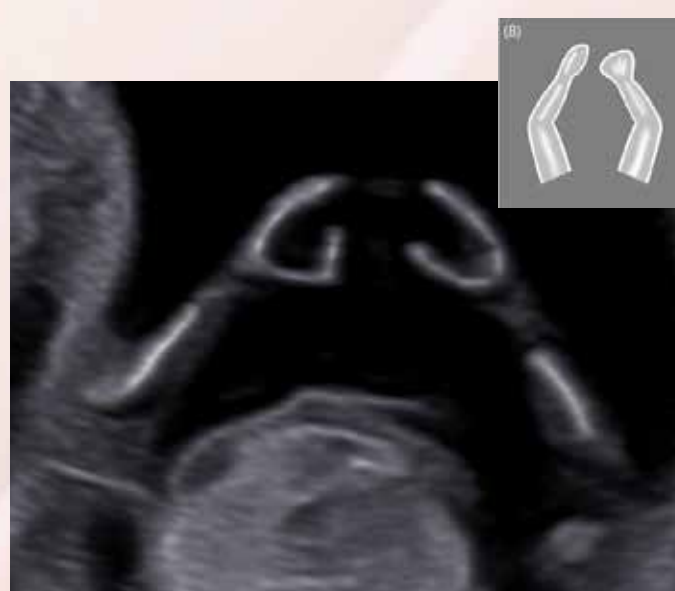Coeur



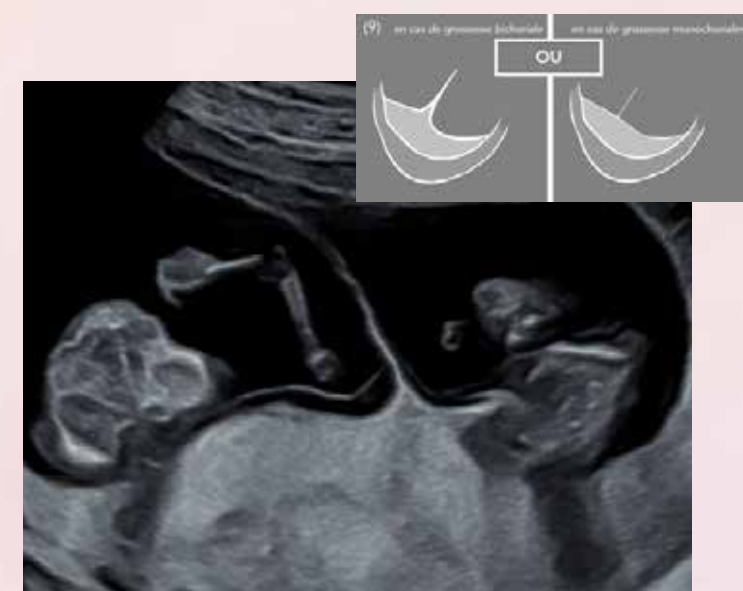2 fémurs



Membres inférieurs

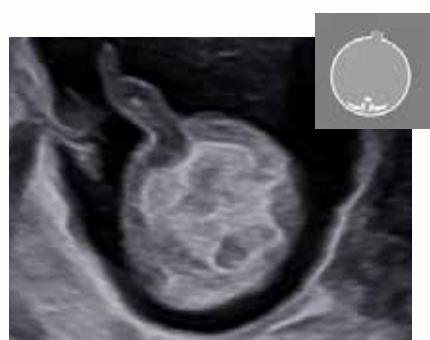

Membres supérieurs

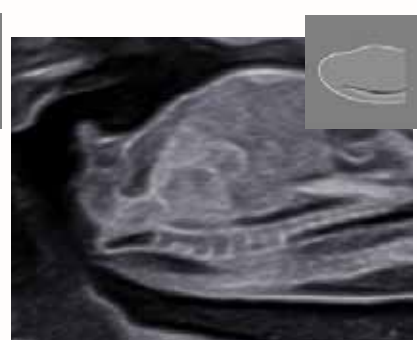

Chorionicité

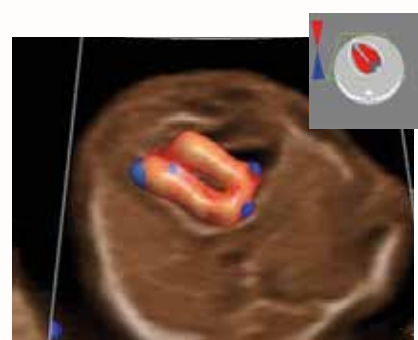
### Images Complémentaires



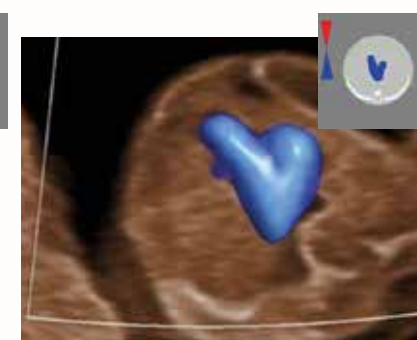
Insertion du  
cordon



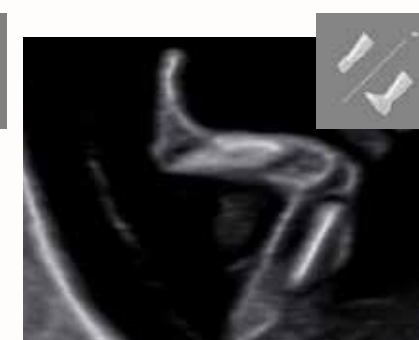Rachis



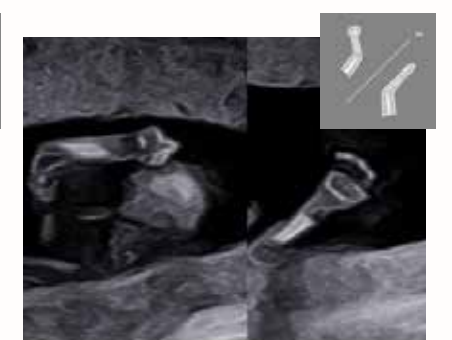
4 cavités  
cardiaques



Coupe  
des crosses



3 segments  
inférieurs



3 segments  
supérieurs