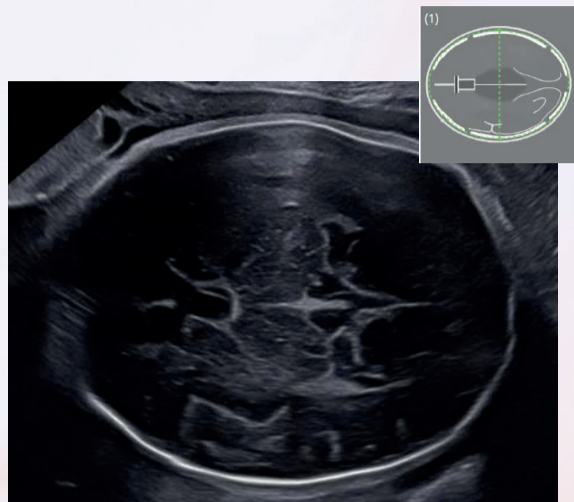
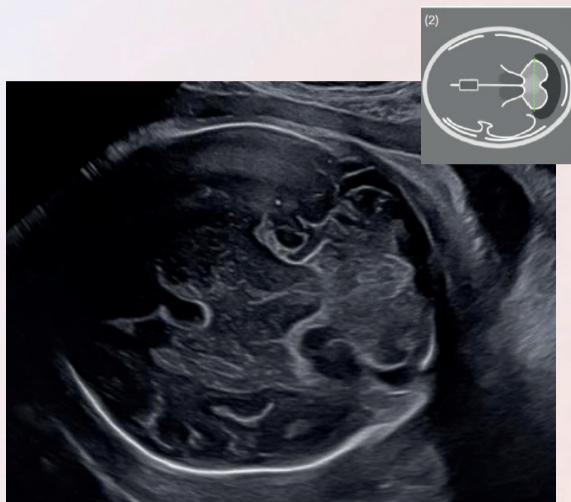


Iconographie recommandée par la CNEOF

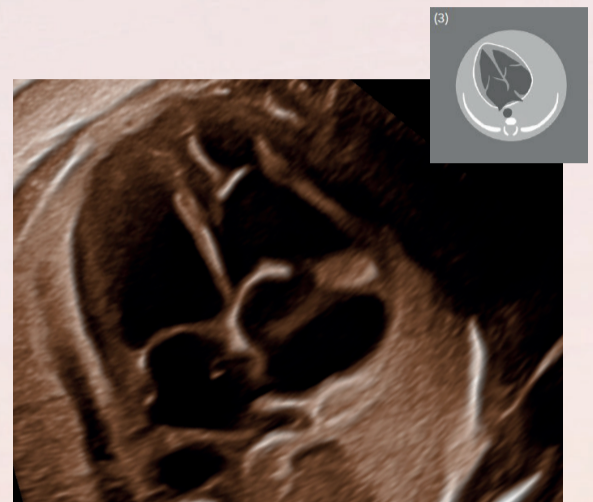
Trimestre 3



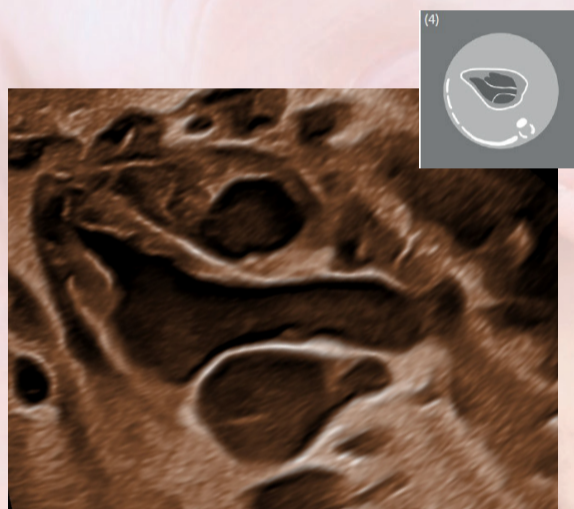
BIP PC



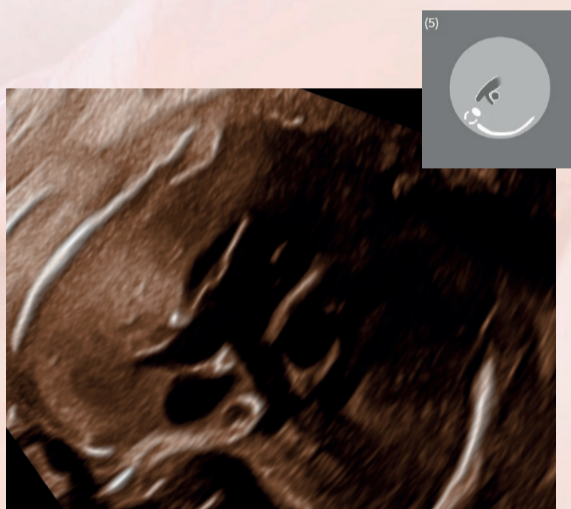Cervelet



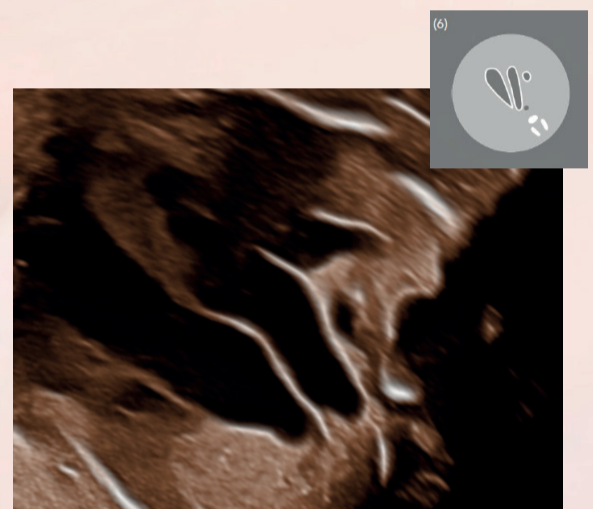
4 cavités cardiaques



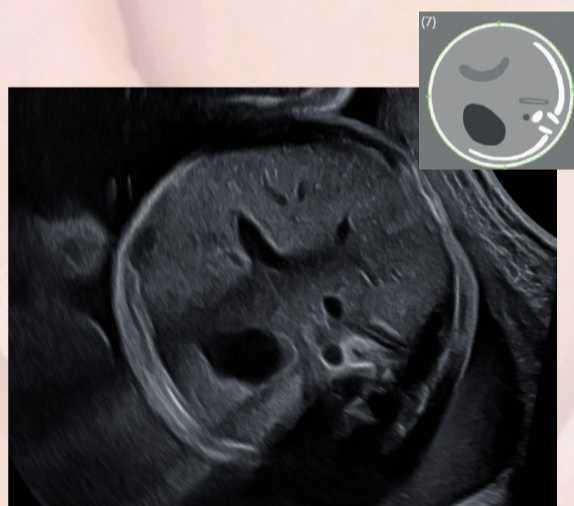
VG aorte



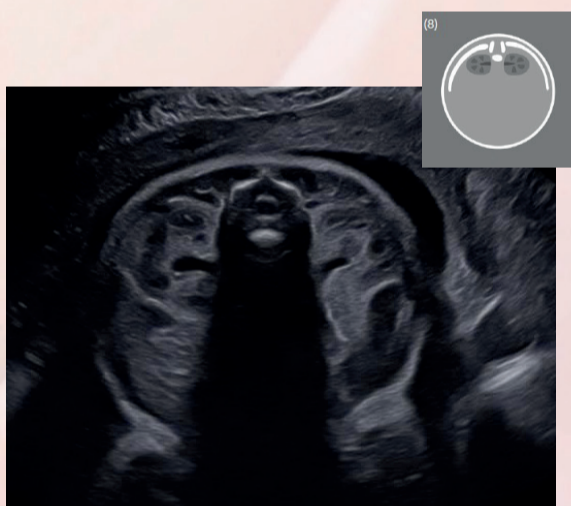
Bifurcation AP



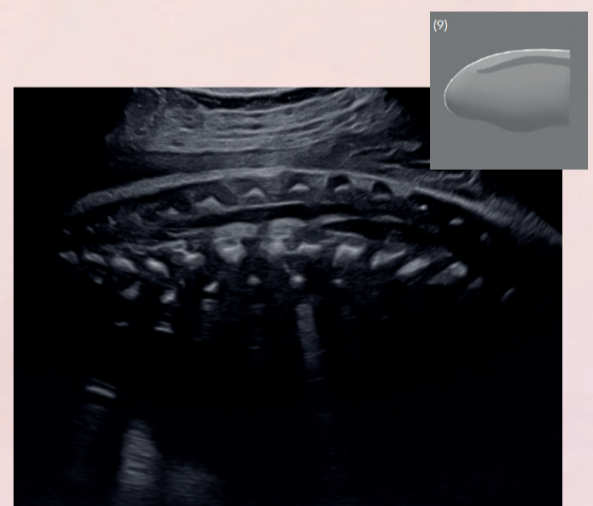Coupe des crosses



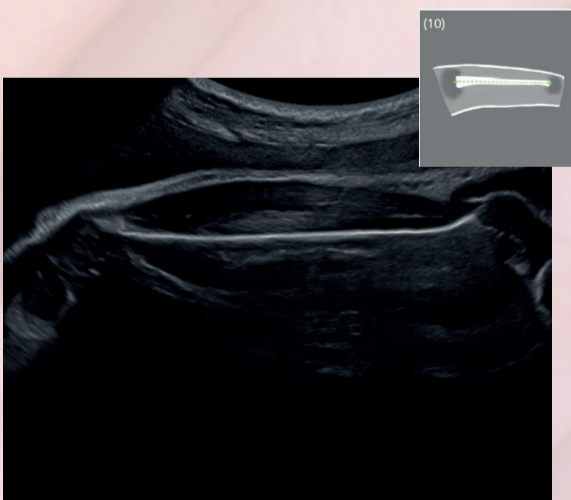
Abdomen



Reins



Rachis



Fémur